

Esthetic Treatment of a Periodontal Patient with Prefabricated Composite Veneers and Fiber-Reinforced Composite: Clinical Considerations and Technique

CLAUDIO NOVELLI, DMD

ABSTRACT

The advances in periodontal therapy and the clinical success of adhesive dentistry have changed the way dentists treat periodontal patients. As more teeth are saved, the demand for functional and esthetic restoration of periodontally involved teeth grows. Once, these teeth were restored with full-coverage splinted restorations, whereas today, adhesive techniques provide less invasive and less complicated treatment options.

This paper presents a novel adhesive combination of fiber-reinforced composite and prefabricated composite veneers to restore function and esthetics in a periodontal patient with severe bone and attachment loss. After successful completion of the periodontal treatment, fiber-reinforced composite has been bonded to the buccal surface of the maxillary anterior teeth in order to control teeth mobility. At the same appointment, prefabricated composite veneers have been bonded to the splinted teeth in order to restore esthetics. The final result shows full integration of contemporary adhesive techniques for single-appointment, minimally invasive treatment of a periodontal patient.

CLINICAL SIGNIFICANCE

This paper describes the use of fiber-reinforced composite and prefabricated composite veneers for the treatment of severe periodontal patients with a minimally invasive, single-appointment technique.

(J Esthet Restor Dent 27:4–12, 2015)

INTRODUCTION

Thanks to improved therapy and earlier diagnosis today, many patients can recover from periodontal disease and retain their teeth for possibly a lifetime.^{1–5} However, recovery is not completed until the esthetic sequelae of the disease have been successfully treated and the smile restored to his natural appearance.

As periodontal disease progresses and bone and attachment get lost, teeth drift, diastemata open, gingival margins recede, dark roots get exposed, interdental tissue shrinks, and black triangles form in the embrasure spaces.^{6–8} This dental and gingival alterations tend to persist even after healing from the

disease with major social and psychological implications for the patient and a negative impact on his strive to maintain optimal oral health.^{9,10}

Many of this esthetic alterations today can be treated and the smile returned to a more natural and attractive appearance. However, when severe bone and attachment loss have compromised teeth stability, treatment is complicated by the need to splint the mobile teeth.

In the past, splinting of periodontally mobile teeth was recommended based on the assumption that tooth stabilization had a direct relationship to periodontal healing and gain in attachment.^{11,12} Recently a number

Via Pontiroli 9/7, Bogliasco, GE, Italy

of studies investigated these assumptions and found lack of correlation between teeth mobility and periodontal disease healing.^{13–18} However, even if teeth mobility is not a causative agent of periodontal disease, teeth stabilization of periodontally mobile teeth is indicated for effective occlusal treatment and prevention of secondary occlusal trauma (injury resulting from normal occlusal forces applied to teeth with inadequate periodontal support).^{19–24} Recent *in vivo* studies show that secondary trauma from occlusion is a frequent finding in periodontal patients and its quantity and quality is positively correlated with the extent and severity of the disease.^{25–28}

Teeth splinting in periodontal patients is also indicated when teeth mobility becomes a functional limitation and interferes with eating and speaking. Teeth mobility can be very distressing for the periodontal patient and is often referred on top of the list of chief complaints. Although successful treatment of the inflammation can result in decrease of teeth mobility, this can never be complete in case of severe bone loss. In such cases, teeth splinting is the only way to completely stabilize the teeth and allow comfortable function for the periodontal patient.^{29–32}

Teeth splinting has been traditionally accomplished with full-coverage cast restorations. Crowns joined together have proved to be effective to stabilize teeth and to restore esthetics, but it is a very aggressive treatment with extensive tooth structure removal and possible root canal therapy.^{33–36} Not to mention that full-coverage restorations typically require subgingival margin placement in patients at high risk of gingival recession and margins exposure.^{37,38}

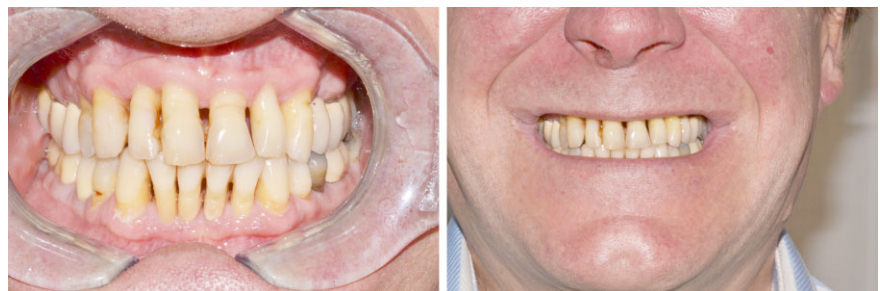A popular alternative treatment for splinting periodontally mobile teeth is fiber-reinforced composite. This technique combines the adhesive property of composite resin with the strength of a reinforcing fiber to provide stabilization with no need for tooth preparation because retention is accomplished by resin adhesion to etched enamel.^{39–42} However, fiber-reinforced composite splinting has some limitations mostly due to the tendency of the composite to wear and the splint to debond. Fiber-reinforced composite splinting is also a purely stabilization technique and does not provide any esthetic improvement for the patient.^{43–46}

This paper presents an alternative technique for splinting periodontally mobile teeth. Fiber-reinforced composite is bonded to the buccal surface of mobile teeth to provide effective stabilization with reduced risk of composite wear and splint debonding. At the same appointment, prefabricated composite veneers are bonded to the splinted teeth to improve the appearance of the smile with minimally invasive teeth preparation. The combination of fiber-reinforced composite and composite veneer forms a monobloc adhesive restoration and restores teeth stability and esthetics in a single appointment with a cost-effective, noninvasive treatment.

CASE PRESENTATION

The patient was a 44-year-old man referred for esthetic treatment after completion of periodontal therapy. His chief complaints were exposed roots and black spaces in between the teeth (Figure 1).

FIGURE 1. Preoperative frontal and lateral views. Periodontal tissues are healthy but the natural appearance of the smile has been severely compromised by the progression of the disease.



At the time of the visit, the patient was in a periodontal maintenance program, which included regular hygiene recalls every 2–3 months and periodical radiographical and microbiological testing. Tissues were healthy and free of inflammation; however, radiographic examination revealed severe generalized bone loss with less than 20% residual bone in the anterior region (Figure 2).

Despite the extensive loss of supporting tissue, the upper and lower anterior teeth were stable because they have been splinted in the initial phase of the periodontal treatment. The original lower splint was still in place whereas the upper splint had to be replaced because of recurrent adhesive failures.

Because the lower anterior teeth were not mobile and not a primary esthetic concern for the patient, the treatment plan for the mandibular arch was limited to class V composite restorations to mask root exposures and no further treatment was indicated at this time. The patient was much more concerned with the appearance of the upper anterior teeth and with the not totally reliable stability provided by the maxillary splint.

The treatment options for the maxillary teeth were discussed with the patient, and due to his relatively young age, a minimally invasive treatment was recommended. It was decided to use Ribbond polyethylene fiber-reinforced composite bonded to the buccal surface from tooth #13 to 23 to splint the mobile teeth and Edelweiss prefabricated composite veneers

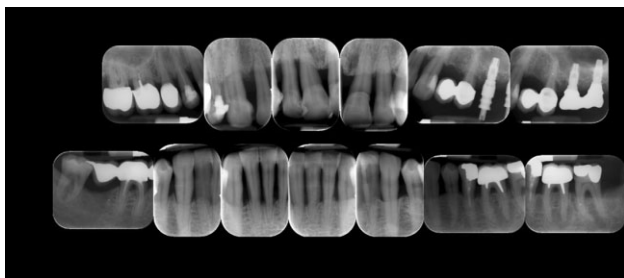


FIGURE 2. Preoperative X-rays. Significant generalized bone loss with less than 20% residual bone in the upper and lower anterior teeth.

from tooth #14 to 23 to restore the appearance of the smile.

At the scheduled appointment, the asymmetrical gingival profile of the central incisors was addressed first. The buccal pocket of tooth #21 was sculpted with a Nd:Yag laser (Smarty A10, Deka, Italy) to reposition the gingival zenith 1.5 mm apically and 1.5 mm distally. Once an ideal gingival symmetry was accomplished, teeth from #13 to 23 have been prepared for Edelweiss veneers. Tooth preparation included a 0.2- to 0.5-mm buccal reduction with supragingival chamfer margin. No extension in the gingival embrasures was necessary because Edelweiss veneers are buccal only and do not extend lingual to the contact point.

After tooth preparation, a 3-mm polyethylene fiber-reinforced composite (Ribbond—ULTRA, Ribbond, Seattle, WA, USA) was cut to the exact length and bonded to the buccal surfaces from canine to canine at approximately the same height of the contact points (Figure 3). Bonding was accomplished with an etch-and-rinse adhesive (Scotchbond Multipurpose Plus, 3M ESPE, Saint Paul, MN, USA) and a flowable composite (Filtek Supreme Ultra Flowable, 3M ESPE). Because Ribbond-ULTRA has excellent adaptation properties and minimal thickness (0.12 mm), it could be bonded flat on the buccal surface with no need for extra tooth preparation (Figure 4).

Once the teeth have been splinted, the second part of the appointment was dedicated to restore esthetics with prefabricated Edelweiss veneers (Edelweiss Veneers, Edelweiss-Dentistry, Hoerbranz, Austria) (Figure 5). Edelweiss veneers are available as canine, lateral, and central incisor shapes in three different sizes (small, medium, and large) that can be eventually adjusted to fit specific patient's requirements. For this patient, veneers size small were fitting right and no adjustment was required.

Before bonding, the inside of the veneers was slightly abraded with a coarse diamond bur and conditioned with a proprietary resin primer (Direct Veneer Bond, Edelweiss-Dentistry) agitated 20 seconds and light




FIGURE 3. Ribbond-ULTRA polyethylene fiber cut to the exact length from canine to canine.

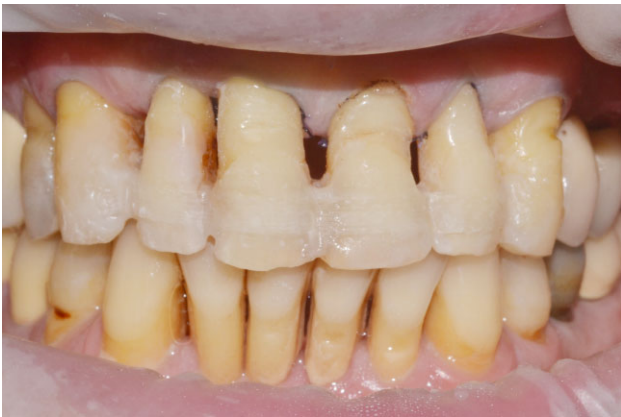

FIGURE 4. Teeth #13 to 23 splinted with buccal fiber-reinforced composite. Note the tight adaptation of the fiber to the tooth surface with minimal increase in thickness.




FIGURE 5. Edelweiss veneer kit. The kit includes veneers for the six anterior teeth plus a special bicuspid veneer.



FIGURE 6. The inside of Edelweiss veneer is roughened with a coarse bur and conditioned with Direct Veneer bond light cured 20 seconds.

cured 20 seconds (Figure 6). The purpose of the surface roughening was to increase micromechanical retention whereas the resin primer promoted chemical adhesion to the prepolymerized composite shell.

After teeth etching with 35% orthophosphoric acid (Ultra-etch, Ultradent, South Jordan, UT, USA) and conditioning with a single-step adhesive (Dentin Bond, Edelweiss-Dentistry), the veneers have been loaded with a nanofilled composite (Edelweiss Direct, Edelweiss-Dentistry) and light cured in position for 60 seconds with an high power LED curing light (Valo, Ultradent) (Figure 7).

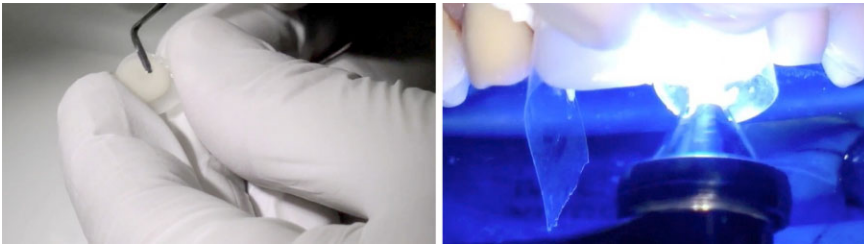

FIGURE 7. Edelweiss veneer are loaded with a nanofilled composite and light cured in position.

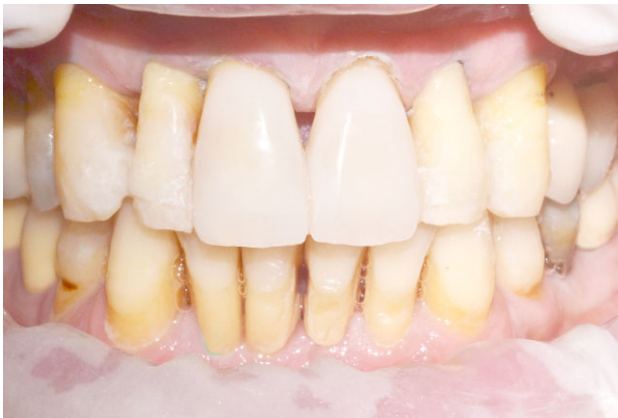

FIGURE 8. Finishing of the margins with Profin oscillating tips.

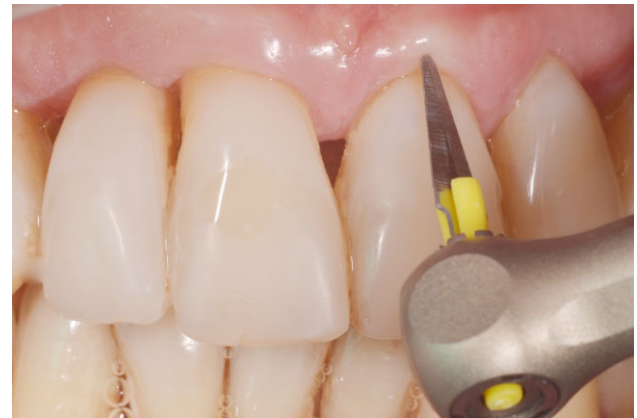

FIGURE 9. Central incisor veneers bonded in place serve as a reference for positioning all the other veneer.

The shade of composite used for bonding the veneers was SB (Skin-Bleach shade from the proprietary Edelweiss shade guide; Edelweiss-Dentistry) which is exactly the same composite shade used to fabricate the actual Edelweiss veneer shells. SB shade was selected for this patient because the extra length of the teeth required to extend the composite gingivally to allow complete coverage of the exposed root. By using the same SB shade, a perfect blending was achieved between the composite gingival extension and the Edelweiss veneer.

After complete curing, the margins of the veneers have been finished under microscope magnification with coarse, medium, and fine grit tips mounted on an oscillating handpiece (Profin PDX, Dentatus, Spanga, Sweden, USA) followed by composite finishing discs (Sof-Lex XT, 3M ESPE) and interproximal finishing strips (Sof-Lex, 3M ESPE) (Figure 8).

The order of veneer cementation started from the central incisors followed by laterals, canines, and

bicuspids. The central incisor veneers have been bonded first because once the correct vertical alignment and incisal edge position were confirmed by looking at the standing patient from speaking distance, they served as reference for proper positioning of all the other veneers (Figure 9).

Once all the Edelweiss veneers were bonded and the occlusion checked for anterior incisal and lateral canine guidance, the patient was dismissed. He returned 6 months later for a recall appointment included in a clinical trial for the evaluation of the Edelweiss veneers/Ribbon splinting technique (Figure 10). At the 6 months recall, the patient was happy with the esthetic result and he reported that his teeth feel very firm and solid since the buccal splint was placed. At the clinical examination, all the Edelweiss veneers showed no marginal discoloration and a smooth and glossy surface comparable with natural enamel. Evaluation of functional (absence of fractures, marginal adaptation) and biological properties (tooth integrity, periodontal response, postoperative sensitivity) was fully satisfactory.

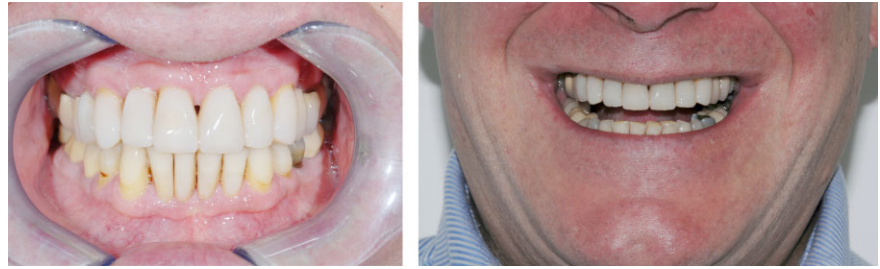

FIGURE 10. Final view after bonding Edelweiss veneers #14–23.

DISCUSSION

Although fiber-reinforced composite is a popular alternative to traditional full-coverage splinted restorations for the treatment of periodontally mobile teeth, the technique has some limitations.^{33–36} The main limitation is the reduced longevity because of composite wear through the fiber. If composite wears to the point of exposing the fiber, it weakens the splint and the fiber becomes a source of irritation to the tongue.^{37–39} Another limitation is the tendency of the splint to debond under repeated tensile stress when the forces of occlusion function against the adhesion.³² Finally, the choice of optimal fiber position and size is frequently limited by the opposing teeth contacts.^{40,41} Most of these limitations occur in the maxillary arch and in closed bites whereas mandibular fiber-reinforced composite provides generally higher survival rate and better clinical performance.^{42,43}

To position the fiber-reinforced composite on the buccal side of the maxillary teeth has the potential to overcome the limitations of the traditional lingual splint. Longevity will be increased because composite is protected from functional wear. Adhesion will be improved because the embedded fiber is now on the tensile side and occlusal forces are directed in a more favorable direction.^{44,45} Finally, no limitation exists for optimal fiber positioning because there is no occlusal contact with the opposing teeth.

Of course, once fiber-reinforced composite is bonded to the buccal, some form of veneering is required to mask the fiber and to restore natural esthetics. Previous experience with cast metal Maryland bridges suggests not to use a rigid restoration for such purpose.^{46–50} The high debonding rate of Maryland bridges in periodontal

patients has been linked to the rigidity of metal that transfers the entire shear and torsional stress generated by the mobile teeth to the adhesive interface.^{51,52} Strassler and Serio showed that high elasticity modulus metal structures present the highest level of interfacial adhesive stress whereas flexible composite material demonstrate the most favorable stress transfer within the tooth/restoration complex.⁵³

Because Edelweiss composite veneers have a low elasticity modulus and a resilient component that allow reduced stress transfer to the adhesive interface, they are expected to perform well when bonded to periodontally mobile teeth. The low elasticity modulus of Edelweiss veneers (20 GPa) is similar to that of Ribbond (19 GPa), and once bonded together, composite veneers and fiber-reinforced composite behave like a monolayer restoration with minimal interfacial stress and optimal biomechanics.

However, favorable biomechanical behaviour is not the only feature that makes Edelweiss veneers suitable for the treatment of periodontal patients. Another relevant feature is the limited thickness of the composite shell especially in the cervical third (0.2 mm) where the combination of thin and translucent composite provides optimal contact lens effect and invisible restoration margins. This is a significant benefit for periodontal patients because invisible margins can be routinely placed supragingivally with improved soft tissue response.

Excellent soft tissue response was found in the presented case and it was likely due not only to the supragingival margin location of the restoration, but also to the atraumatic nature of the technique. Because

the entire clinical procedure was completed in a single appointment with no need for tissue displacement, impression taking, temporary placement/removal, and other maneuvers typically required for traditional indirect restorative techniques, the trauma to the delicate gingival tissues was minimized and the risk of biological complications was reduced.

This single-appointment, minimally invasive technique is a more conservative, less complicated, less expensive alternative to traditional full-coverage restorations for the treatment of severe periodontal patients. However, although long-term follow-up studies of full-coverage splinted restorations have been published, there are no comparable data for the presented adhesive technique, and its efficacy is still to be validated by the test of time. It is possible that the laser-vitrified inorganic surface of Edelweiss veneers will not preserve its glossy and smooth appearance as long as ceramic or that the adhesive combination of composite veneers and fiber-reinforced composite will not be as durable as traditional cast metal restorations. But less durable might still be preferable to more aggressive treatment especially in young patients to postpone more invasive treatment until a later stage.

To answer the question of the medium/long-term performance and to evaluate the efficacy of the technique, a clinical trial named the Splinted Veneers Project is actually in progress at the Excellence Dental Network clinics in Milan, Florence, and Rome. Patients successfully treated for periodontal disease and enrolled in the periodontal maintenance program participate in the project. Patient inclusion criteria include full natural teeth in the upper arch with mobility 1–2 and no signs of inflammation. The same operator (Claudio Novelli) splints the upper front teeth with buccal 3-mm Ribbond fiber-reinforced composite and bonds Edelweiss composite veneers to the splinted teeth at the same appointment. Both periodontal criteria and modified United States Public Health Service criteria are scored at the immediate postoperative control and then every 6 months for the next 6 years. At the moment, 12 patients are participating to this prospective clinical study and the intermediate 3-year results will be available in late 2014.

DISCLOSURE

The author does not have any financial interest in the companies whose materials are included in this article.

REFERENCES

1. Goldman M, Ross I, Goteiner D. Effect of periodontal therapy on patients maintained for 15 years or longer. *J Periodontol* 1986;57:347–53.
2. Wilson T, Glover M, Malik A, et al. Tooth loss in maintenance patients in a private periodontal practice. *J Periodontol* 1987;58:231–5.
3. Nabers C, Stalker W, Esparza D, et al. Tooth loss in 1535 treated periodontal patients. *J Periodontol* 1988;59:297–300.
4. Chace R, Low S. Survival characteristics of periodontally-involved teeth: a 40-year study. *J Periodontol* 1993;64:701–5.
5. Roshna T, Nandakumar K. Generalized aggressive periodontitis and its treatment options: case reports and review of the literature. *Case Rep Med* 2012;Article ID 535321. [Epub ahead of print].
6. Fu JH, Su CY, Wang HL. Esthetic soft tissue management for teeth and implants. *J Evid Based Dent Pract* 2012;12(3 Suppl):129–42.
7. Craddock H, Yorke V, Chan M. Cosmetic rehabilitation following successful treatment of aggressive periodontitis. *Dent Update* 2007;34:91–6.
8. Cirelli JA, Cirelli CC, Holzhausen M, et al. Combined periodontal, orthodontic, and restorative treatment of pathologic migration of anterior teeth: a case report. *Int J Periodontics Restorative Dent* 2006;26(5):501–6.
9. Cash TF. The psychology of physical appearance: aesthetics, attributes, and images. In: Cash TF, Pruzinsky T, editors. *Body images—development, deviance, and change*. New York (NY): Guilford; 1990, pp. 51–79.
10. McCaul KD, Glasgow RE, Gustafson C. Predicting levels of preventive dental behaviors. *J Am Dent Assoc* 1985;111:601–5.
11. Fleszar TJ, Knowles JW, Morrison EC, et al. Tooth mobility and periodontal therapy. *J Clin Periodontol* 1980;7:33–8.
12. Kegel W, Selipsky H, Phillips C. The effect of splinting on tooth mobility. I. During initial therapy. *J Clin Periodontol* 1979;6:45–58.
13. Poison AM, Adams RA, Zander A. Osseous repair in the presence of active tooth hypermobility. *J Clin Periodontol* 1983;10:370–9.
14. Ericsson I, Lindhe J. Lack of significance of increased tooth mobility in experimental periodontitis. *J Periodontol* 1984;55:447–52.

15. Bhaskar SN, Orban B. Experimental occlusal trauma. *J Periodontol* 1955;26:270–84.
16. Glickman I. Inflammation and trauma from occlusion, co-destructive factors in chronic periodontal disease. *J Periodontol* 1963;34:5–10.
17. Glickman I, Smulow JB, Vogel G, Passamoti G. The effect of occlusal forces on healing following mucogingival surgery. *J Periodontol* 1966;37:319–25.
18. Lindhe J, Ericsson I. The influence of trauma from occlusion on reduced but healthy periodontal tissues in dogs. *J Clin Periodontol* 1976;3:110–22.
19. Page RC, Offenbacher S, Schroeder HE, et al. advanced in the pathogenesis of periodontitis. Summary of developments, clinical implications and future directions. *Periodontol* 2000 1997;14:216–48.
20. The American Academy of Periodontology. The pathogenesis of periodontal disease. *J Periodontol* 1999;70:457–70.
21. Polson AM. The relative importance of plaque and occlusion in periodontal disease. *J Clin Periodontol* 1986;13:923–7.
22. Spear FM. Fundamental occlusal therapy considerations. In: McNeill C, editor. *Science and practice of occlusion*. Chicago (IL): Quintessence Publishing Co; 1997, pp. 421–34.
23. Glickmann I, Smulow JB. Alterations in the pathway of gingival inflammation in humans. *J Periodontol* 1965;36:141–7.
24. Glickmann I, Smulow JB. Further observations on the effect of trauma from occlusions in humans. *J Periodontol* 1967;38:280–93.
25. Branschofsky M, Beiker T, Schafer R. Secondary trauma from occlusion and periodontal disease. *Quintessence Int* 2011;42:515–22.
26. Bernhardt O, Gesch D, Look JO. The influence of dynamic occlusal interferences on probing depth and attachment levels. *J Periodontol* 2006;77:506–16.
27. Nunn ME, Harrel SK. The effect of occlusal discrepancies on periodontitis. Relationship of initial occlusal discrepancies to initial clinical parameters. *J Periodontol* 2001;72:485–94.
28. Harrel SK, Nunn ME. The association of occlusal contacts with the presence of increased periodontal probing depth. *J Periodontol* 2009;36:1035–42.
29. Tarnow DP, Fletcher P. Splinting of periodontally involved teeth: indications and contraindications. *N Y State Dent J* 1986;52:24–5.
30. Mosedale RF. Current indications and methods of periodontal splinting. *Dent Update* 2007;34:168–78.
31. Bernal G, Carvajal JC, Muñoz-Viveros CA. A review of the clinical management of mobile teeth. *J Contemp Dent Pract* 2002;3:10–22.
32. Strassler H. Tooth stabilization improves periodontal prognosis. A case report. *Dent Today* 2009;28:88–92.
33. Brägger U, Hirt S. Complication and failure rates of fixed dental prostheses in patients treated for periodontal disease. *Clin Oral Implants Res* 2010;22(1):70–7.
34. Siegel SC, Driscoll CF, Feldman S. Tooth stabilization and splinting before and after periodontal therapy with fixed partial dentures. *Dent Clin North Am* 1999;43:45–76.
35. Cordaro L, Ercoli C, Rossini C, et al. Retrospective evaluation of complete-arch fixed partial dentures connecting teeth and implant abutments in patients with normal and reduced periodontal support. *J Prosthet Dent* 2005;94(4):313–20.
36. Kreissl ME. Complex dental rehabilitation in a periodontally compromised patient. Part 2: treatment and discussion. *Eur J Esthet Dent* 2007;2(3):322–35. Autumn.
37. Valderhaug J. Periodontal conditions and carious lesion after the insertion of fixed prosthesis: a 10 years follow-up study. *Int Dent J* 1980;30:296–304.
38. Valderhaug J, Birkeland M. Periodontal conditions in patients 5 years following insertion of fixed prosthesis. *J Oral Rehabil* 1976;3:237–43.
39. Ayna E, Celenk S. Polyethylene fiber-reinforced composite inlay fixed partial dentures: two-year preliminary results. *J Adhes Dent* 2005;7:337–42.
40. Unlu N, Belli S. Three-year clinical evaluation of fiber-reinforced composite fixed partial dentures using prefabricated pontics. *J Adhes Dent* 2006;8:183–8.
41. Pollack RP. Non-crown and bridge stabilization of severely mobile, periodontally involved teeth. A 25-year perspective. *Dent Clin North Am* 1999;43(1):77–103.
42. Freilich MA, Meiers JC, Duncan JP, et al. Clinical evaluation of fiber-reinforced fixed bridges. *J Am Dent Assoc* 2002;133:1524–34.
43. Strassler HE, Serio FG. Stabilization of the natural dentition in periodontal cases using adhesive restorative materials. *Periodontal Insights* 1997;4(3):4–10.
44. Pollack RP. Non-crown and bridge stabilization of severely mobile, periodontally involved teeth—a 25 year perspective. *Dent Clin North Am* 1999;43(1):77–103.
45. Strassler HE, Karbhari V, Rudo D. Effect of fiber reinforcement on flexural strength of composite. *J Dent Res* 2001;80(Special Issue):221. (abstract no. 854).
46. Strassler H, Brown C. Periodontal splinting with a thin high-modulus polyethylene ribbon. *Compend Contin Educ Dent* 2001;22(8):696–708.
47. Van Heumen C, Van Dijken JM, Tanner J. Five-year survival of 3-unit fiber-reinforced composite fixed partial dentures in the anterior area. *Dent Mater* 2009;25(6):820–7.
48. Strassler HE, LoPresti J, Scherer W, Rudo D. Clinical evaluation of a woven polyethylene ribbon used for splinting. *Esthet Dent Update* 1995;6:79–84.

49. Pollack RP. Non-crown and bridge stabilization of severely mobile, periodontally involved teeth—a 25 year perspective. *Dent Clin North Am* 1999;43(1):77–103.
50. Strassler HE, Haeri A, Gultz JP. New-generation bonded reinforcing materials for anterior periodontal tooth stabilization and splinting. *Dent Clin North Am* 1999;43:105–26.
51. Karbhari VM, Strassler H. Effect of fiber architecture on flexural characteristics and fracture of fiber-reinforced dental composites. *Dent Mater* 2007;23:960–96.
52. Iniguez I, Strassler HE. Polyethylene ribbon and fixed orthodontic retention and porcelain veneers: solving an esthetic dilemma. *J Esthet Dent* 1998;10:52–9.
53. Strassler HE, Serio FG. Stabilization of the natural dentition in periodontal cases using adhesive restorative materials. *Periodontal Insights* 1997;4(3):4–10.

Reprint requests: Claudio Novelli, DMD, Via Pontiroli 9/7, I 6031 Bogliasco (GE), Italy; Tel.: +39 (0)55281619; Fax +39(0)552676204; email: cnovelli@libero.it