

# Bonded anterior orthodontic retainers

Roger A. Solow, DDS

Craniofacial growth occurs throughout adulthood for both orthodontically treated and untreated patients.<sup>1,2</sup> One aspect of skeletal change is a decrease of the intercanine dimension with an increase in anterior tooth irregularity.<sup>3,4</sup> Other factors may contribute to this misalignment, such as the anterior component of force—a vertical occlusal force on posterior teeth creating a horizontal vector of force at the anterior teeth.<sup>5,6</sup> Although postorthodontic anterior crowding is commonly thought of as relapse or treatment failure, documented long-term skeletal changes show that malalignment is predictable unless permanent retention is provided.<sup>7,8</sup> Retention should be considered an integral phase of orthodontic treatment.<sup>9</sup> Retainers are designed to prevent movement from relapse (a return to the original tooth position) and instability (eruption of teeth to establish contact secondary to vertical skeletal growth).<sup>10</sup>

Removable retainers permit normal oral hygiene with brush and floss, but rely on patient compliance for consistent use, are bulky, can be lost, and result in slightly more crowding than fixed retainers.<sup>11,12</sup> Fixed retainers typically attach to anterior teeth, are much less bulky, and do not have a patient compliance issue since they work as long as they remain bonded in place. They require diligent interproximal cleaning with floss threaders to avoid periodontal inflammation.<sup>13</sup> Common designs for fixed retainers are a thick wire bonded only to the canines or a thinner, flexible wire bonded to all the anterior teeth. Alternatively, fiber-reinforced composite (FRC) can be used to bond all the anterior teeth.

Both canine-to-canine and all-anterior teeth bonded retention have been shown to be effective.<sup>14,15</sup> Because slight facial and incisal movement is still possible with canine-to-canine retainers, they do not preserve the anterior teeth alignment as well as when all the anterior teeth are bonded.<sup>15,16</sup> Bonded retainers usually fail on a single tooth without the entire retainer dislodging.<sup>17</sup> This is more easily detected by the patient with a canine-to-canine retainer than an all-anterior teeth bonded retainer. Flexible wire retainers can fail at the composite resin-tooth bond, the wire-composite resin interface subsequent to abrasion, and by fracture of the wire itself.<sup>18</sup> Reports of these types of failures for canine-canine retainers range from 20.4% to 38% at 5 and 20 years, respectively. Failures for all-anterior teeth bonded retainers range from 27.3% to 32.2% at 3 and 5 years, respectively.<sup>12,14-16</sup> Several reports have noted significant tooth movement, even root perforation of the buccal bone cortex, despite an all-anterior teeth bonded retainer remaining intact.<sup>19,20</sup> These events have been ascribed to inadvertent torque during placement of the wire or mechanical deformation of the wire from hard foods. FRC retainers have a marked increased flexural strength compared to plain composite resin which extends the life of the retainer. The high tensile strength fibers transfer stress away from the weak polymer matrix of the composite resin.<sup>21</sup> Glass and polyethylene have been used as the fiber components, of FRC retainers. They are metal-free,

which can be an advantage for nickel-sensitive patients. Tacke et al reported higher failure rates of glass fiber FRC (51%) compared to flexible wire (12%) at 2 years.<sup>22</sup> Ardeshtna found a 33% survival rate of unidirectional glass FRC retainers at 12 months.<sup>23</sup> Bolla et al found comparable failure rates at 6 years between glass fiber and flexible wire in both maxillary (21.4% and 22.2%, respectively) and mandibular (11.8% and 15.6%, respectively) retainers.<sup>24</sup>

Ribbon (Ribbon) is a stretch-resistant, woven, polyethylene fiber that provides multidirectional reinforcement, does not fray when cut, and is very adaptable to tooth contours. It is very esthetic, although it is mainly used in retainers placed in low visibility areas. Saleh et al showed a comparable failure rate of Ribbon FRC to a flexible wire retainer at 18 months: 50% vs 36.5% in the maxilla and 42.6% vs 37.8% in the mandible, respectively.<sup>17</sup> The differences were not statistically significant. Scribante et al also found comparable failure rates between the same retainer types at 1 year: polyethylene (InFibra, TP Italia) at 14.5% and flexible wire at 22.5%.<sup>25</sup> The difference was not statistically significant. Strassler et al used Ribbon for fixed retainers, periodontal splints, and tooth replacement on 13 patients and reported no failures at 26.5 months.<sup>26</sup>

Rose et al found in a 24-month study that Ribbon retainers remained in place for a mean of 11.5 months and flexible wire retainers for a mean of 23.5 months.<sup>27</sup> This was proved to be an invalid study as the manufacturer's instructions for Ribbon placement were not followed when the composite resin layer was polymerized prior to Ribbon application, which resulted in a thick, low-strength composite resin layer with no integration into the Ribbon and no interdigitation of the Ribbon into the lingual embrasures.<sup>28,29</sup> The failure mode at the Ribbon-composite resin junction was consistent with an improper application.

All retainers are susceptible to problems over a long term. Since most patients are not continually monitored by the orthodontist, the general dentist has the responsibility to evaluate orthodontic retainers. If a problem is detected, the dentist can repair/replace the retainer or refer the patient to an orthodontist. Since many dentists are not trained to bend wire for an intimate fit with the teeth, the use of an FRC bonded anterior orthodontic retainer is presented as an option. The concept, materials, and technique are a variation of a bonded periodontal splint that is typically placed by general dentists.<sup>30</sup> The retainer can be fabricated directly in the mouth or indirectly with a cast-derived matrix for rapid placement when a rubber dam cannot be used or if the patient requires a short appointment.

## Direct technique

Measure the length of the retainer with floss and cut the same length of Ribbon-ULTRA with ceramic scissors. Isolate and clean the anterior teeth with a diamond bur or air abrasion. Etch the teeth with 37% phosphoric acid, rinse and dry. Apply unfilled

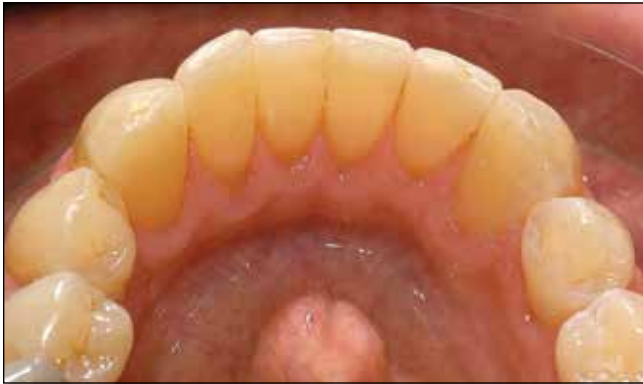

Fig. 1. Lingual view of the postorthodontic alignment.

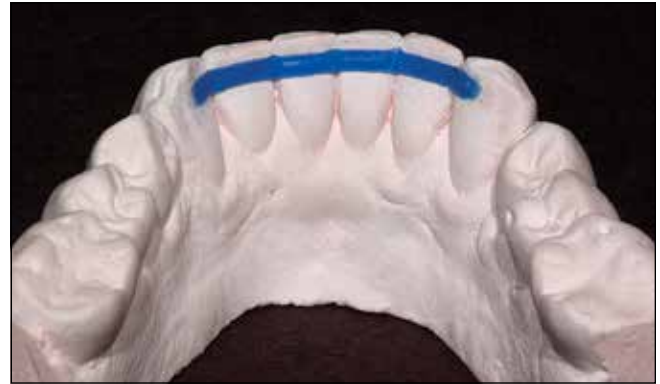

Fig. 2. Fast-set stone cast with 12-gauge half-round wax at the level of the interproximal contacts to maintain gingival embrasure space.

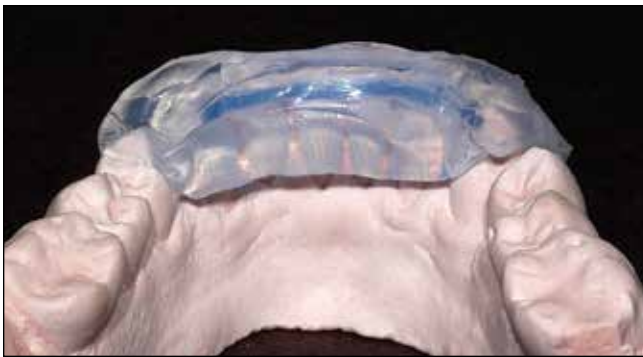


Fig. 3. Clear vinyl polysiloxane matrix extending past the incisal edge and onto adjacent teeth for accurate intraoral positioning.

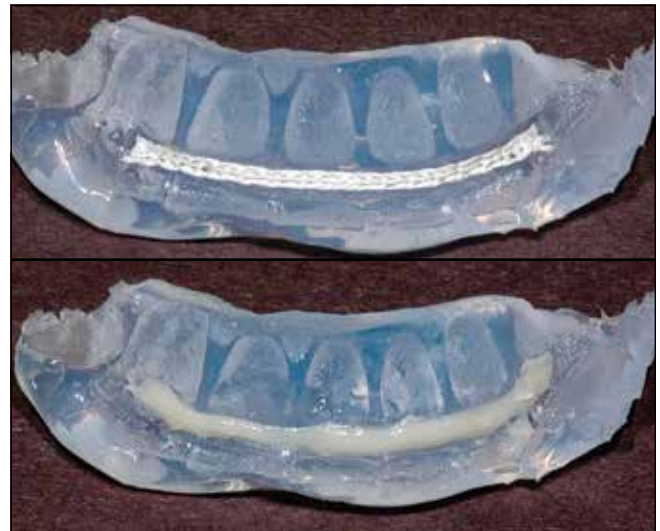

Fig. 4 *Top*. Ribbon in matrix recess formed by the wax shape. *Bottom*. Ribbon pressed into the filled composite resin. The matrix will adapt the composite resin and place Ribbon closely against the teeth.

resin to the teeth, thin with air, and light polymerize for 10 seconds. Wet the Ribbon-ULTRA with a thin layer of unfilled resin. Apply a thin band of filled composite resin to the teeth at the level of the interproximal contacts and press in the Ribbon-ULTRA, tucking into the interproximals for close adaptation. Light polymerize for 60 seconds. Cover the surface with flowable composite and polymerize for 60 seconds. Contour and polish with carbide finishing burs and rubber points.

### Indirect technique

Clean the anterior teeth (Fig. 1). Obtain an alginate impression and pour it in fast-set stone (Snap-Stone, Whip Mix Corporation). Separate the cast after 5 minutes and place 12-gauge half-round wax (Otto Frei) at the level of the contacts (Fig. 2). Tack the wax down with a heated wax instrument and place indents to ensure close adaptation of the Ribbon interproximally. Place a 3 mm layer of clear vinyl polysiloxane (Memosil, Heraeus Kulzer) to cover the lingual surface and incisal edge (Fig. 3). Isolate the anterior teeth. Measure a length of Ribbon that fits into the clear matrix recess. Etch the teeth with 37% phosphoric acid, rinse, and dry. Apply unfilled resin to the teeth, thin with air, and light polymerize for 10 seconds.

Wet the Ribbon with a thin layer of unfilled resin. Apply a band of filled composite resin into the recess of the matrix and lightly press in the Ribbon (Fig. 4). Immediately place the matrix and confirm proper seating. Light polymerize for 60 seconds. Contour and polish with finishing burs and rubber points (Fig 5). One concern with a retainer placed with this protocol is that it is rigid and will not tolerate stress as well as a flexible wire retainer.<sup>17</sup> However, this technique is used to predictably splint mobile, periodontally involved teeth and place bonded pontics, which present more demanding situations.<sup>31</sup> Proper bonding technique and a 1 mm bulk of composite over the Ribbon to resist abrasion are important for retainer longevity.<sup>32</sup> Ribbon also has the advantage of being thin, which enhances patient comfort. Ribbon-ULTRA is 0.12 mm thick x 1 mm wide. The manufacturer's recommended technique

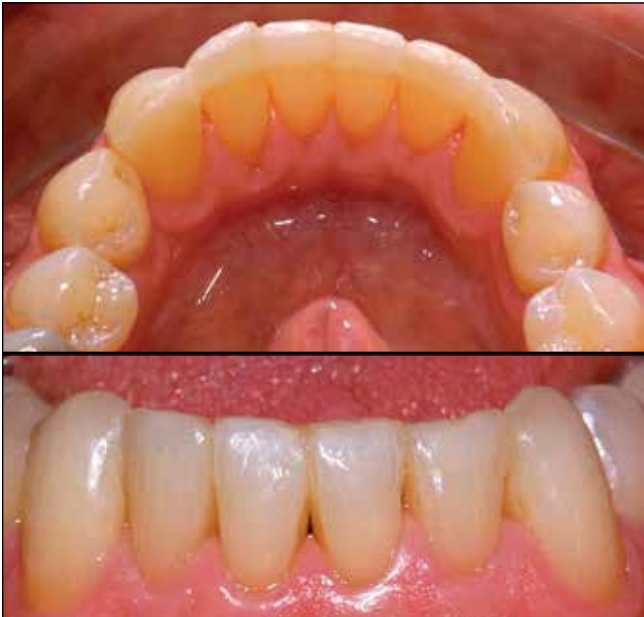

Fig. 5 *Top*. Lingual view of finished composite resin/Ribbon bonded retainer. The surface is smooth and continuous with natural contour for patient comfort. *Bottom*. Facial view of bonded retainer. Note the open gingival embrasure space to facilitate oral hygiene with floss threaders.

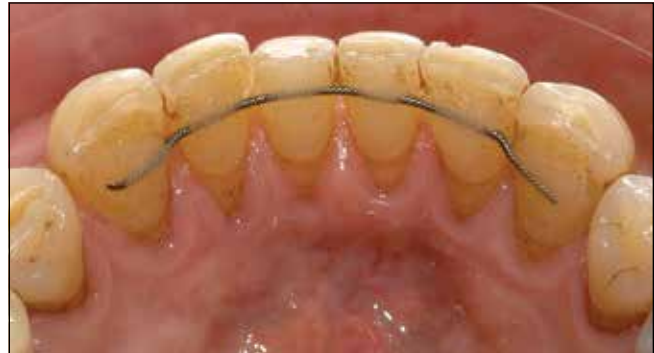

Fig. 6. Wire-composite resin retainer. The rough spiral wire and gaps between the wire and teeth can trap food and irritate the patient's tongue.

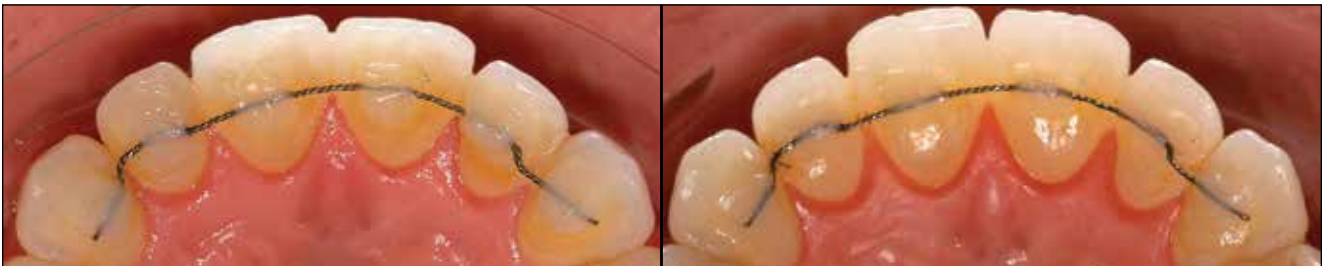

Figure 7. *Left*. Excess, rough composite resin was a constant irritant to the patient and an interference to proper lower incisor contact. *Right*. Recontoured and polished composite with 1 mm of coverage over the wire to resist abrasion and loss of wire retention.

creates a polished, continuous surface from canine-to-canine without exposed rough spiral wire or gaps between the wire and the lingual embrasures (Fig. 6). These areas can trap food, and the rough wire may not be tolerable to some patients. Dentists can also improve existing wire retainers by recontouring excess composite resin (Fig. 7).

### Author information

Dr. Solow is in private practice in Mill Valley, California, and a member of the visiting faculty at the Pankey Institute, Key Biscayne, Florida.

### Disclaimer

The author has no financial, economic, commercial, and/or professional interests related to topics presented in this article.

### References

1. Lewis AB, Roche AF. Late growth changes in the craniofacial skeleton. *Angle Orthod.* 1988;58(2):127-135.
2. Bishara SE, Treder JE, Damon P. Changes in the dental arches and dentition between 25 and 45 years of age. *Angle Orthod.* 1996;66(6):417-422.
3. Bondevik O. Changes in occlusion between 23 and 34 years. *Angle Orthod.* 1988; 68(1):75-80.
4. Sinclair PM, Little RM. Maturation of untreated normal occlusions. *Am J Orthod.* 1983; 83(2):114-123.
5. Southard TE, Behrents RG, Tolley EA. The anterior component of occlusal force. Part 1. Measurement and distribution. *Am J Orthod Dentofacial Orthop.* 1989;96(6):493-500.
6. Southard TE, Behrents RG, Tolley EA. The anterior component of occlusal force. Part 2. Relationship with malalignment. *Am J Orthod Dentofacial Orthop.* 1990;97(1):41-44.
7. Little RM, Wallen TR, Riedel RA. Stability and relapse of mandibular anterior alignment-first premolar extraction cases treated by traditional edgewise orthodontics. *Am J Orthod.* 1981;80(4):349-365.
8. Lyotard N, Hans M, Nelson S, Valiathan M. Short term postorthodontic changes in the absence of retention. *Angle Orthod.* 2010;80(6):1045-1050.

9. Parker WS. Retention—retainers may be forever. *Am J Orthod Dentofacial Orthop.* 1989;95(6):505-513.
10. Driscoll-Gilliland J, Buschang PH, Behrents RG. An evaluation of growth and stability in untreated and treated subjects. *Am J Orthod Dentofacial Orthop.* 2001;120(6):588-597.
11. Schott TC, Schlipf C, Glasl B, Schwarzer CL, Weber J, Ludwig B. Quantification of patient compliance with Hawley retainers and removable functional appliances during the retention phase. *Am J Orthod Dentofacial Orthop.* 2013;144(4):533-540.
12. Artun J, Spadafora AT, Shapiro PA. A 3-year follow-up study of various types of orthodontic canine-to-canine retainers. *Eur J Orthod.* 1997;19(5):501-509.
13. Levin L, Samorodnitsky-Naveh GR, Machtei EE. The association of orthodontic treatment and fixed retainers with gingival health. *J Periodontol.* 2008;79(11):2087-2092.
14. Booth FA, Edelman JM, Proffit WR. Twenty-year follow-up of patients with permanently bonded mandibular canine-to-canine retainers. *Am J Orthod Dentofacial Orthop.* 2008;133(1):70-76.
15. Renkema AM, Renkema A, Bronkhorst E, Katsaros C. Long-term effectiveness of canine-to-canine bonded flexible spiral wire lingual retainers. *Am J Orthod Dentofacial Orthop.* 2011;139(5):614-621.
16. Renkema AM, Al-Assad S, Bronkhorst E, Weindel S, Katsaros C, Lisson JA. Effectiveness of lingual retainers bonded to the canines in preventing mandibular incisor relapse. *Am J Orthod Dentofacial Orthop.* 2008;134(2):179e1-179e8.
17. Saleh P, Zarif Najafi H, Roeinpeikar SM. Comparison of survival time between two types of orthodontic fixed retainer: a prospective randomized clinical trial. *Prog Orthod.* 2013;14:25.
18. Artun J, Spadafora AT, Shapiro PA. A 3-year follow-up study of various types of orthodontic canine-to-canine retainers. *Eur J Orthod.* 1997;19(5):501-509.
19. Katsaros C, Livas C, Renkema AM. Unexpected complications of bonded mandibular lingual retainers. *Am J Orthod Dentofacial Orthop.* 2007;132(6):838-841.
20. Pazera P, Fudalej P, Katsaros C. Severe complication of a bonded mandibular lingual retainer. *Am J Orthod Dentofacial Orthop.* 2012;142(3):406-409.
21. Arhun N, Arman A. Fiber-reinforced technology in multidisciplinary chairside approaches. *Indian J Dent Res.* 2008;19(3):272-277.
22. Tacke MP, Cosyn J, De Wilde P, Aerts J, Govaerts E, Vannet BV. Glass fibre reinforced versus multistranded bonded orthodontic retainers: a 2 year prospective multi-centre study. *Eur J Orthod.* 2010;32(2):117-123.
23. Ardeshtna AP. Clinical evaluation of fiber-reinforced-plastic bonded orthodontic retainers. *Am J Orthod Dentofacial Orthop.* 2011;139(6):761-777.
24. Bolla E, Cozzani M, Doldo T, Fontana M. Failure evaluation after a 6-year retention period: a comparison between glass fiber-reinforced (GFR) and multistranded bonded retainers. *Int Orthod.* 2012;10(1):16-28.
25. Scribante A, Sfondrini MF, Broggin S, D'Allocco M, Gandini P. Efficacy of esthetic retainers: clinical comparison between multistranded wires and direct-bond glass fiber-reinforced composite splints. *Int Dent J.* 2011;2011:548356.
26. Strassler HE, Scherer W, LoPresti J, Rudo D. Long term clinical evaluation of a woven polyethylene ribbon used for tooth stabilization and splinting. *J Israel Orthod Soc.* 1997;7:11-15.
27. Rose E, Frucht S, Jonas IE. Clinical comparison of a multistranded wire and a direct-bonded polyethylene ribbon-reinforced resin composite used for lingual retention. *Quintessence Int.* 2002;33(8):579-583.
28. Winkler D. Clinical comparison of a multistranded wire and a direct-bonded polyethylene-reinforced resin composite used for lingual retention [Letter to the Editor]. *Quintessence Int.* 2004;35(5):348.
29. Rudo, DN. Clinical comparison of a multistranded wire and a direct-bonded polyethylene-reinforced resin composite used for lingual retention [Letter to the Editor]. *Quintessence Int.* 2004;35(5):348.
30. Strassler HE, Brown C. Periodontal splinting with a thin high-modulus polyethylene ribbon. *Compendium Cont Educ Dent.* 2001;22(8):696-700.
31. Unla N, Belli S. Three-year clinical evaluation of fiber-reinforced composite fixed partial dentures using prefabricated pontics. *J Adhes Dent.* 2006;8(3):183-188.
32. Bearn DR, McCabe JF, Gordon, PH, Aird JC. Bonded orthodontic retainers: the wire-composite interface. *Am J Orthod Dentofacial Orthop.* 1997;111(1):67-74.

## Manufacturers

Heraeus Kulzer, South Bend, IN  
800.435.1785, [www.heraeus-dental-us.com](http://www.heraeus-dental-us.com)

Otto Frei, Oakland, CA  
510.832.0355, [www.ottofrei.com](http://www.ottofrei.com)

Ribbon, Seattle, WA  
800.624.4554, [www.ribbon.com](http://www.ribbon.com)

TP Italia, Gorle Bergamo, Italy  
39.035.452.0001, [www.tpitalia.com](http://www.tpitalia.com)

Whip Mix Corporation, Louisville, KY  
800.626.5651, [whipmix.com](http://whipmix.com)