

Optimum restoration of missing tooth structure

Liviu and Gabriela Steier introduce new guidelines to make for easier treatment decisions

Adhesive resins have completely changed treatment options and indications for destroyed teeth. Modern materials can emulate and simulate the physical properties of natural tooth structure. The in-depth study and understanding of natural tooth anatomy, structure and behaviour in function, combined with resin composite and adhesive knowledge, for dentists opens the door to laboratory-manufactured restorations.

When it comes to restoration, we are confronted on a daily basis by these common questions:

- Can I restore the destruction with a direct composite restoration?
- Is there need for additional reinforcement?
- How to best reinforce the restoration
- What is the best etch/adhesive procedure to be used in this case?
- What resins should I use?

This article intends to address the first three questions in the list above. To gain a more comprehensive understanding, each of the questions requires a detailed explanation.

Introducing new formulas

Let us presume that the outline of a natural tooth crown is a cube. Each wall of this cube is made up of two distinctive structures (dentine and enamel). Dentine and enamel differ in their physical properties but represent a bimaterial assembly. A natural tooth is built to never fail in function.

Rule of thumb

Loss of tooth structure needs to be calculated by determining the ratio of remaining tooth walls. To make this calculation easier, a formula can be applied.

The tooth walls represent the walls of a cube. Each wall is related to five walls. Comparing the walls ratio to the ideal situation will help quantify the amount of remaining tooth structure in relation to the methodology of reinforcement and the kind of rehabilitation required.

Let us describe the five walls and their physical presence or absence:

- Sound tooth: $5/5 = 1$
- One missing wall: $4/5 = 0.8$
- Two missing walls: $3/5 = 0.6$
- Three missing walls: $2/5 = 0.4$
- Four missing walls: $1/5 = 0.2$
- Five missing walls: $0/5 = 0$.

According to the above-mentioned classification, the author suggests that the loss in tooth walls should be used as criteria for restorative procedure selection, while the loss in dentinal wall should be used for the selection of reinforcement.

Selecting the best composite restoration

The following treatment alternatives are available:

- Direct composite restoration
- Semi-direct composite/inlay restoration
- Indirect restoration
- Partial coverage
- Complete cusp coverage.

The direct composite restoration requires tooth structure for good adhesive anchoring into existing dentine and enamel. If the clinician is adequately skilled and familiar with most of the adhesive dentistry secrets, then he/she will extend the indication for direct restorations into even deeply destroyed teeth.

The semi-direct composite restoration opens up a plethora of opportunity for those clinical situations where occlusion, proximal contact points and overall tooth shape are difficult to directly restore.

Indirect restorations are preserved today for extended destruction and tremendous amounts of missing tooth structure. It is always wise to bear in mind that full coverage will imply the removal of the remaining natural tooth substance and in this way reduce the direct adhesive anchorage of resins to dentine or enamel.

The amount of tooth destruction should be calculated

accordingly: number of missing walls/natural number of walls. Relating this formula to the enamel walls results in the indication of treatment method (see table below).

	Direct composite restoration	Semi-direct composite/inlay restoration	Partial coverage	Complete cusp coverage
1	x			
0.8				
0.6	x	x		
0.4	x	x	x	
0.2			x	x

The rehabilitation indication according to tooth wall destruction

Selecting the best reinforcement

The clinician confronted with this question will most certainly think of cusp coverage. But besides this, a plethora of alternatives are available today. It all started with the fibre-reinforced composite posts. Industrial composite reinforced fibres were introduced to anchor restorations in endodontic treated teeth. It was just a step ahead to use available fibres to reinforce direct/indirect composite restorations. Reinforced restorations will help support unsustained enamel/dentine walls as well as big restorations per se.

Different fibres are involved in reinforcement technology: aramid, carbon, ceramics, fibreglass, natural fibres, synthetic fibres or thermoplastics. Rayon was first introduced in 1910, and today several generations of fibres are available for single use, as posts or in braided form.

Fibre posts can be described as unidirectional fibres coated in resins and polymerised industrially. Different external forms can be curved out of the end result, allowing for different forms with or without retention, tapered or parallel, with head retention or without.

When functioning as a composite reinforcement, braid exhibits remarkable properties because it is highly efficient in distributing loads. All the fibres within a braided structure are continuous and mechanically locked; therefore braid has a natural mechanism that evenly distributes load throughout the structure. Braid's efficient load distribution also makes its structure extremely impact resistant. Since all the fibres in the structure are involved in bearing the load, braid absorbs a great deal of energy as it fails. This is why braid is used as fan blade containment in commercial aircraft and in energy absorbing crash structures in Formula One racing cars (www.braider.com).

	No reinforcement	One post	Multiple posts	One mesh	'Onion technique'
1	x				
0.8				x	
0.6		x		x	
0.4		x	x	x	x
0.2			x	x	x

The adhesive reinforcement needed according to tooth wall destruction

In 2007 triaxial braids of leno woven ultra high modulus polyethylene fibre were introduced to reinforce composite resins. This results in a significant increase in flexural characteristics. The reinforcement material showed enhanced levels of strain and energy absorption resulting in a toughening effect of composites (www.ribbon.com).

Deciding when to use posts and when to use meshes requires clarification. We are all looking for cookbook recipes to share the responsibility of our decisions. To offer help, the author offers a new way of classification based on an anecdotal rule of thumb.

The steps between the presented classification numbers can make for a fine definition of the clinical situation.

The following reinforcement alternatives are available:

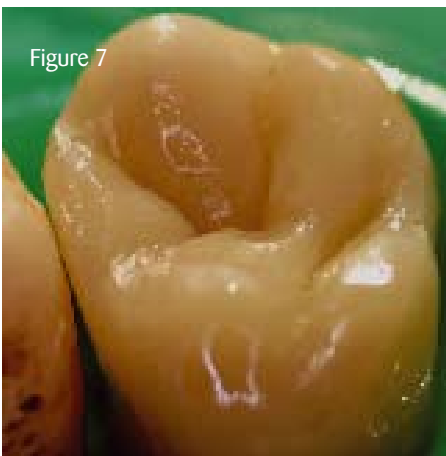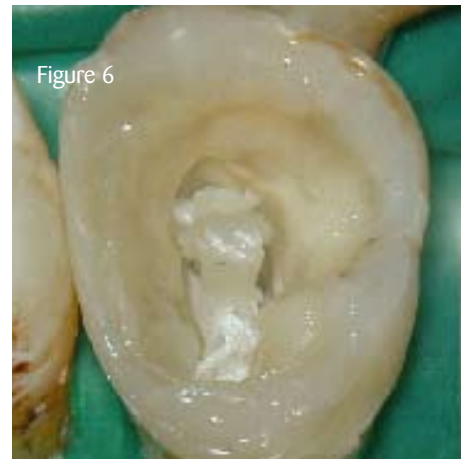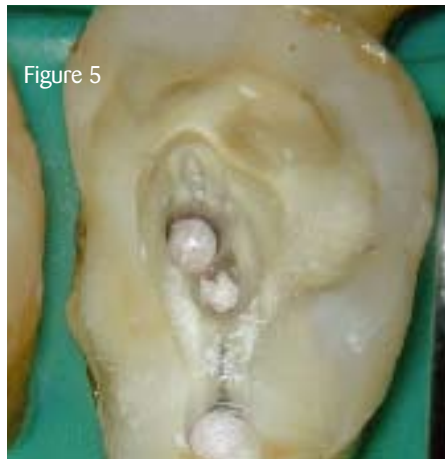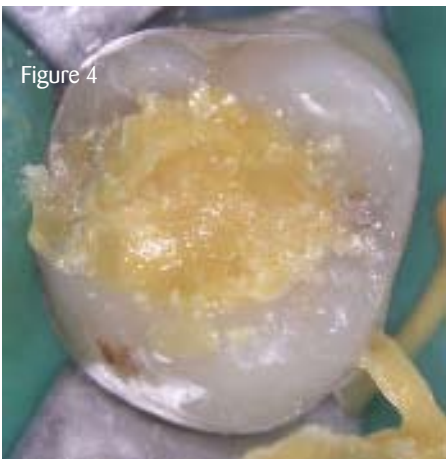
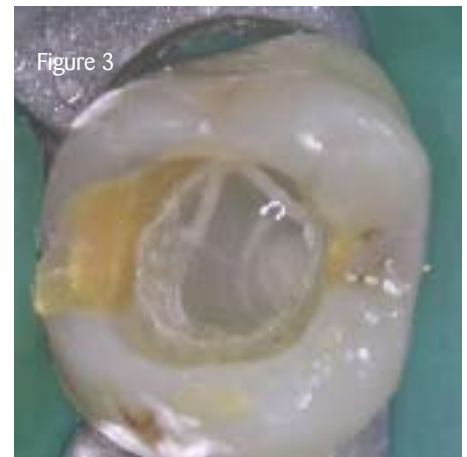
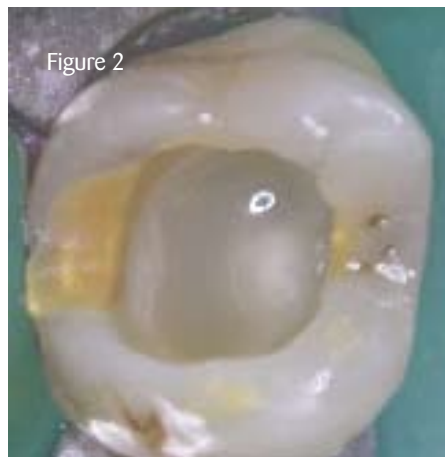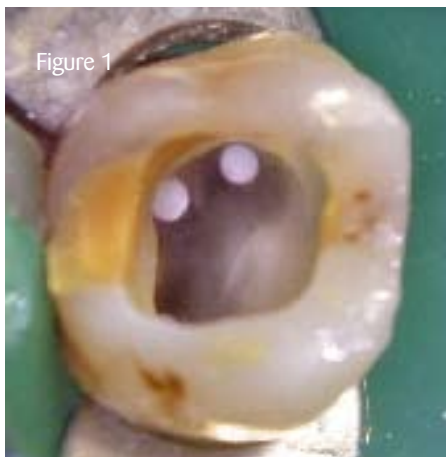1. Unidirectional fibres – either precured as posts or not.
2. Braided fibres (mesh) – either embedded in composite resin or not.

Fibre network has proved to positively change the stress dynamics if incorporated at the natural tooth structure interface (enamel-dentine) - adhesive material (composite-adhesive) or inside the dentinal core.

With braided fibres, different layering techniques can be used: single layer to reinforce the rebuild wall, single or multiple circumferential layering ('onion technique'), additional central placement, and so on.

References

- Belli S et al (2004) Fracture resistance of endodontically treated molar teeth: Various restoration techniques, Continental European Division/Scandinavian Division/Israeli division (CED/NOF/ID) of IADR 2004 Istanbul Meeting (25-28 August 2004)
- Steier L (2003) Wurzelkanalbehandelte Zähne im Kontext adhäsiver Techniken. *ZMK*; 19(5): 1-5
- Steier L (2004) A new perspective on the endodontic restorative continuum. *Endodontic Therapy*; 3(2): 12-15. [PD](#)



Case example

Figure 1: Direct clinical view of a posterior tooth. Situation after root canal treatment. Tooth will be prepared for an indirect restoration **Figure 2:** Direct clinical view of the same posterior tooth immediately after orifice sealing with a flowable composite **Figure 3:** Direct clinical view of the circumferential layered mesh before build up **Figure 4:** Gold coloured build up was syringed into the previous tooth structure. The tooth is ready for the crown preparation **Figure 5:** Direct view of the clinical situation after completion of the root canal treatment. Tooth will be prepared for a direct composite restoration. According to the above mentioned classification, a post or a mesh can be used for anchoring and reinforcement **Figure 6:** To anchor the dental core build up leno woven ultra high modulus polyethylene fibre was used (here Ribbond) and cemented in the orifice. The mesh was previously shaped as an omega loop **Figure 7:** Direct view of the completed direct composite restoration before rubber damn removal. The occlusal morphology mimics the natural look of the neighbouring teeth

[Comments to pd@fmc.co.uk](mailto:pd@fmc.co.uk)

Dr Liviu Steier FICOI FIAG FRSM FADFE, specialist in endodontics (GDC), visiting professor at the University of Florence; has been in private practice since 1985, and he has been working at 20 Wimpole Street since 2006. He lectures worldwide on endodontics and restorative dentistry and has written numerous articles in international dental journals.