



Richard D. Trushkowsky DDS, is co-director for the Advanced Program for International Dentists in Interdisciplinary Dentistry at NYU and Associate Director Advanced Program for International Dentists in Aesthetic Dentistry at NYU. Co-clinicians are Carmen Lopez Laserna Rodriguez DDS, former student in the Advanced Program for International Dentists in Aesthetic Dentistry at NYU and currently Fellow in Advanced Program for International Dentists in Interdisciplinary Dentistry at NYU; and Man Hong Chau DDS, Instructor in the Advanced Program for International Dentists in Aesthetic Dentistry at NYU.

# IMMEDIATE PROVISIONALIZATION BEFORE IMPLANT PLACEMENT

## CASE PRESENTATION | 17

**A**n 18-year-old female presented with tooth No. 7 missing after a history of trauma. At age 7, she fell and the tooth avulsed. It wasn't stored in any "liquid" or ideal environment, and when it was reimplanted, the results were compromised. No endodontic treatment was performed and at age 16, the patient lost the tooth; a temporary was fabricated. Subsequently, she had a bone graft using DynaBlast DBM Paste (Keystone Dental) plus a membrane barrier placed after decortification of the site; another temporary was placed. The patient again lost her temporary, and it was rebonded with resin composite at another clinic.

Looking for a longer-lasting treatment option, the patient came to the Advanced Program for International Dentists in Aesthetic Dentistry at NYU. Her oral hygiene was good; radiographic, oral cancer examinations, and medical history were within normal limits. We decided to create a composite bridge with fiber reinforcement. The selected material was Ribbond bondable reinforcement ribbon, Ribbond-thm Thinner Higher Modulus 3 mm (Ribbond, Inc).

The use of fiber reinforcement provides distinct advantages in composite restorative techniques. The use of ultra-high molecular weight polyethylene (UHMWP) fibers is based on the improvement of the composite resin mechanical properties and behavior. To reinforce the restoration in multiple directions, woven fiber and meshes have been proposed, where isotropic properties are achieved.

Incorporated into composite materials, the fibers provide enhanced fracture resistance, indicating their application even when high stress is present in the oral environment. The 2 key reasons for using the fiber-reinforced composite for this case: minimal removal of sound dental structure and esthetics.

The treatment is described in the figure captions. After a painless, fast, in-office procedure, the patient left very happy and able to smile with new self-confidence.

This was not your typical patient who wanted to improve her smile. Even though she had upper anterior teeth that were out of position, she wanted only her front tooth restored to its original position.

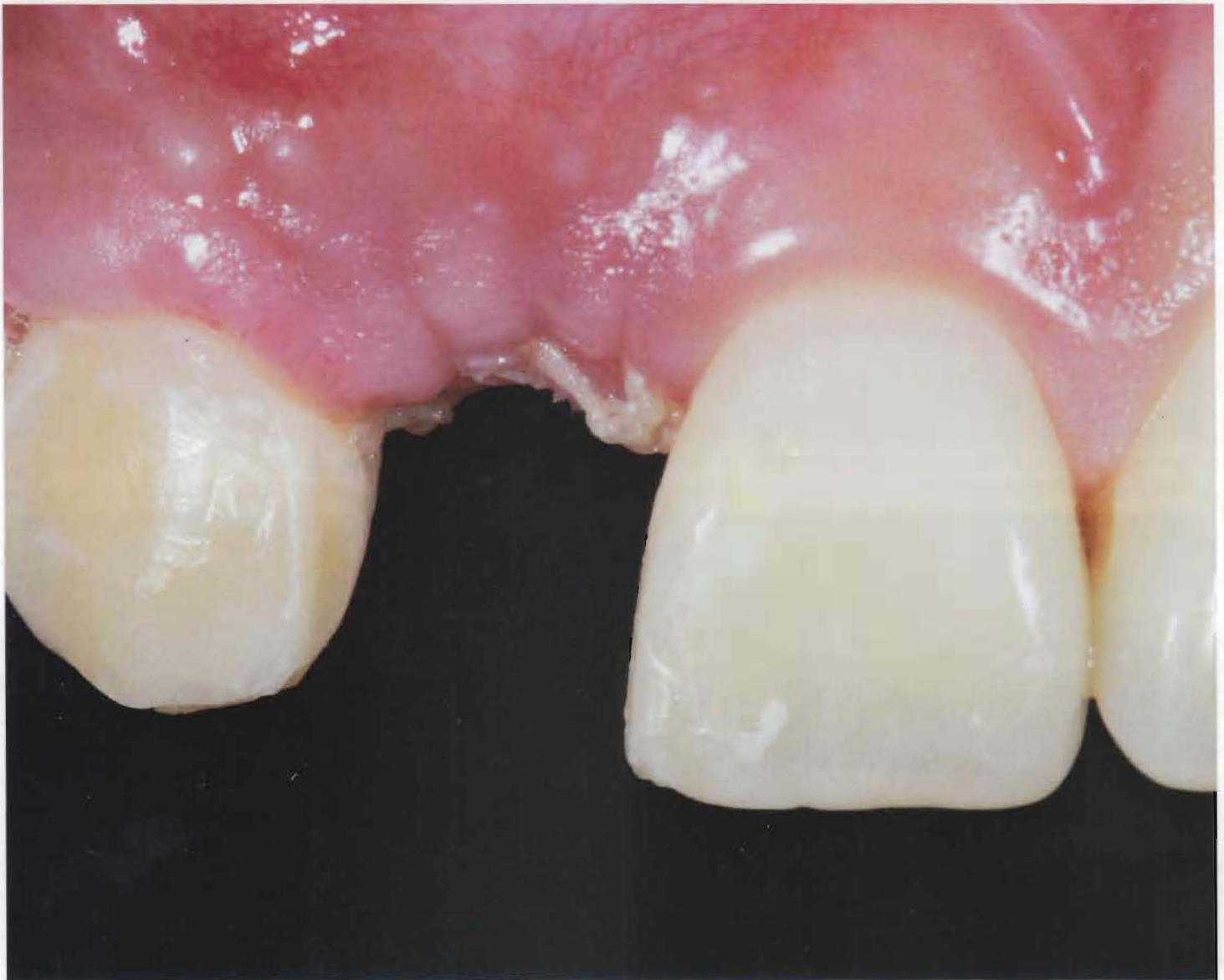

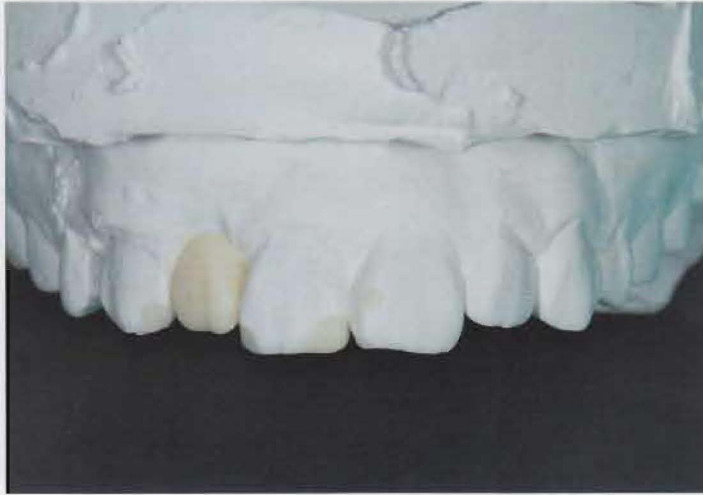
Figure 1—The patient presented with the maxillary right lateral incisor missing and a bone graft.

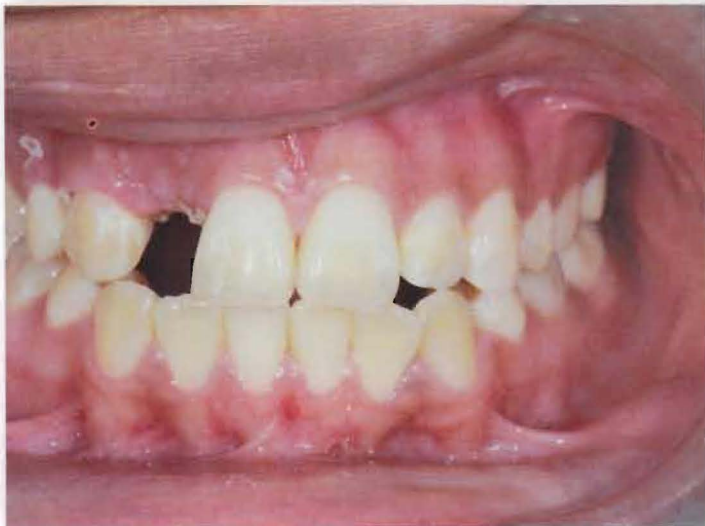

Figure 2—Retracted view of the patient reveals the contra-lateral view of the maxillary left lateral incisor.

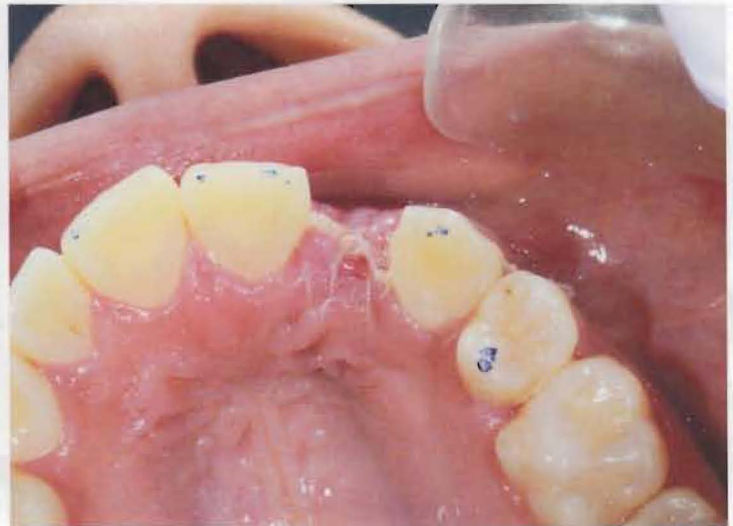

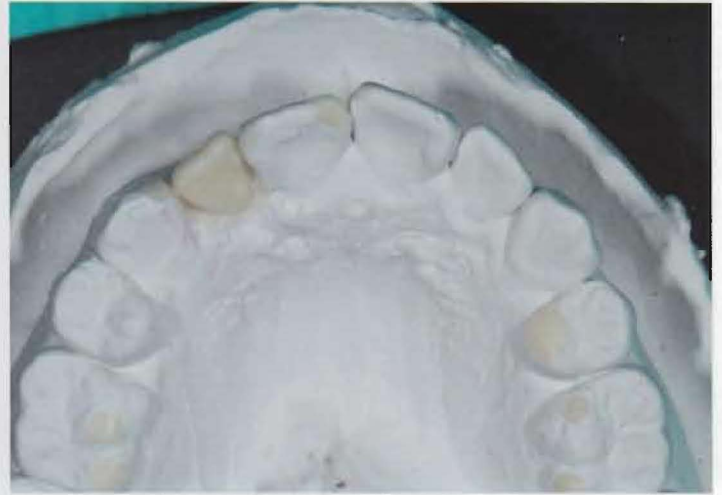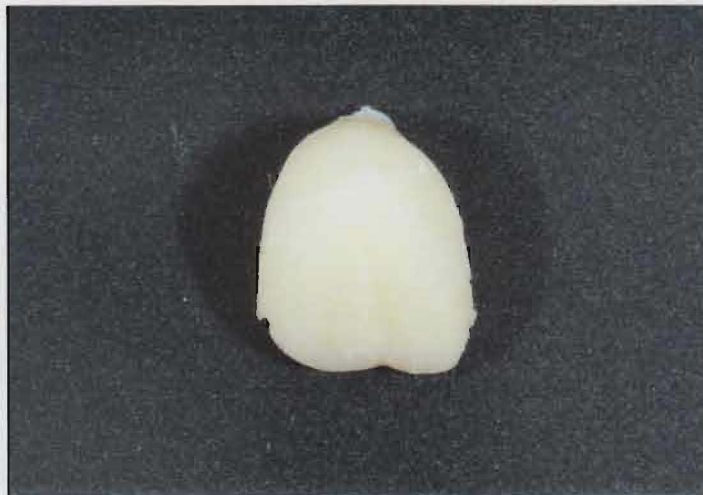Figure 3—Occlusal view of the extraction site illustrates the ridge's buccal/lingual dimensions. Articulating paper indicates centric stops and demonstrates adequate clearance for the fiber and composite on the lingual.



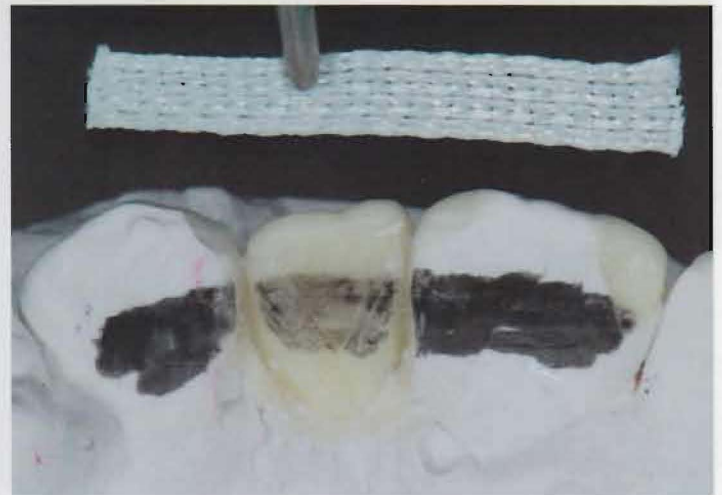**Figure 4**—Labial view of wax-up of tooth No. 7 shows anatomy similar to tooth No. 10 and supporting papilla.



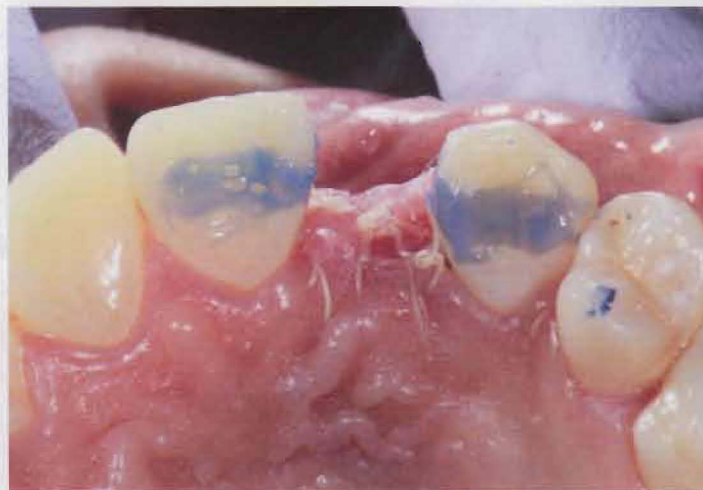**Figure 5**—Occlusal view of wax-up of tooth No. 7 shows proper arch position.



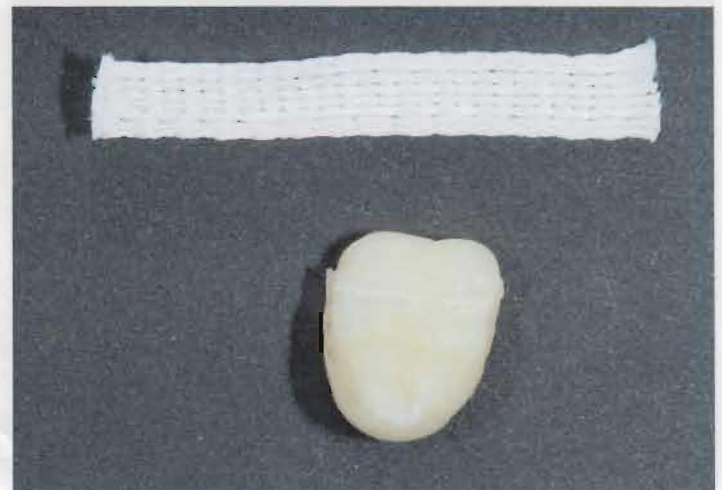
**Figure 6**—We used clear impression material (Memosil, Heraeus Kulzer) to duplicate tooth No. 7 pontic with composite resin. Composite resin pontic was duplicated from the wax-up (shown).



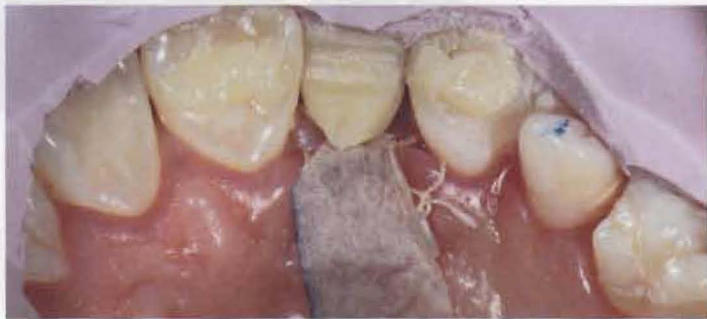**Figure 7**—The provisional bridge. We then cut Ribbond material with special scissors to cover area from the distal of the adjacent central incisor to the distal of the canine. This was used to connect the pontic to the abutments.



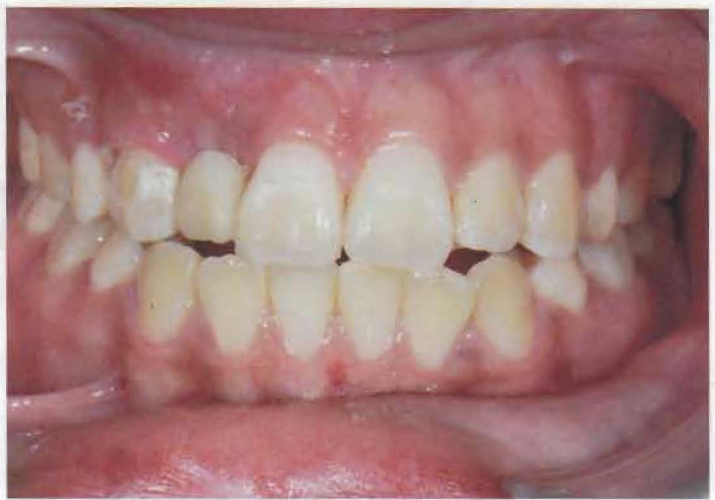**Figure 8**—The adjacent teeth were etched with 35% phosphoric acid for 15 seconds and then Peak LC Bond Resin Adhesive (Ultradent) was placed, air dried, and light-cured for 20 seconds.



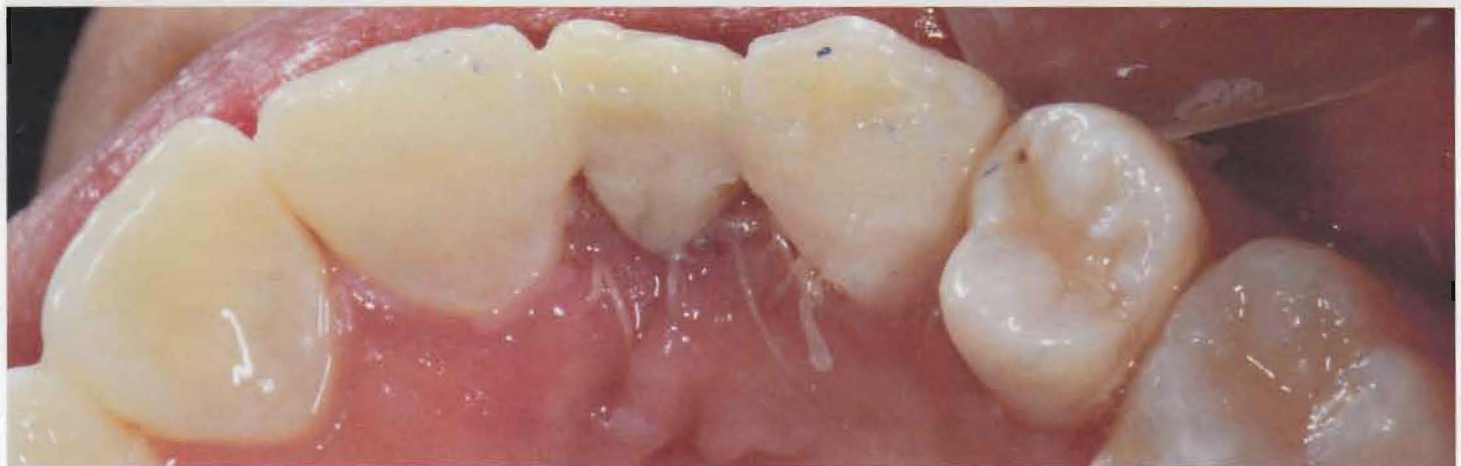**Figure 9**—We cut a groove from mesial to distal of the pontic to accommodate the Ribbond material and composite resin (shown). The Ribbond material was then wetted with flowable composite and excess removed by running a plastic instrument over the surface.



**Figure 10**—A putty stent (Coltene Whaldent) fabricated from the wax-up was used to position the composite pontic in the correct position. We placed composite (Amelogen Plus, Ultradent) on the lingual of the abutments and on the pontic. While still soft, the flowable composite-impregnated Ribbond was pressed into the composite, excess removed, and then light cured for 20 seconds on the lingual of each tooth. Then we placed a layer of flowable composite resin and created a smooth surface with a brush. Occlusion was verified, and any interference was removed as needed. The lingual surface required minimal finishing and polishing.

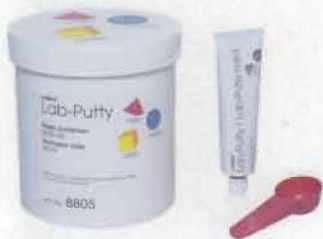

**Figure 11**—Labial view of the composite provisional demonstrates proper positioning and similar appearance to the contra-lateral tooth. The pontic provides support for the soft tissue in the area to initiate site development.



**Figure 12**—Occlusal view of the pontic shows the incisal edge lined up with adjacent teeth.

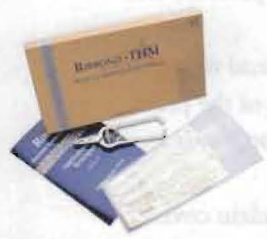#### GO-TO PRODUCTS USED IN THIS CASE



#### LAB PUTTY

Lab-Putty is a polysiloxane laboratory modeling product material with 62 - 67 Shore A hardness. It can be used for model repairs, isolation and denture heat protection, keys and block outs and matrixes to create general occlusion and functional patterns

**COLTÉNE/WHALDENT**  
888.592.9909 ext. 71236  
<http://link.argifocus.com/35Q-236>  
Reader Service 236



#### RIBBOND-THM

Ribbond fiber reinforcement prevents fracture failures in composites and acrylics, ensuring strong and durable prostheses that maintain their strength with continued use. Ribbond's fibers exceed the breaking point of fiberglass, while absorbing less moisture than dental resins.

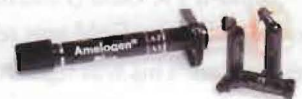**RIBBOND**  
888.592.9909 ext. 71237  
<http://link.argifocus.com/35Q-237>  
Reader Service 237



#### PEAK UNIVERSAL BOND

Peak Universal Bond is the only light-cure adhesive that contains chlorhexidine, which helps ensure long-term bond strengths. It's ideal agent for indirect and direct bonding, and post and core procedures, working equally well with self- and total-etch techniques.

**ULTRADENT**  
888.592.9909 ext. 71238  
<http://link.argifocus.com/35Q-238>  
Reader Service 238



#### AMELOGEN PLUS

Amelogen Plus provides a simple system for creating natural-looking restorations. It balances an intuitive range of shades with strength and high Polishability, and it is suitable for both posterior and anterior restorations. Also, it is nonsticky and does not slump.

**ULTRADENT**  
888.592.9909 ext. 71239  
<http://link.argifocus.com/35Q-239>  
Reader Service 239